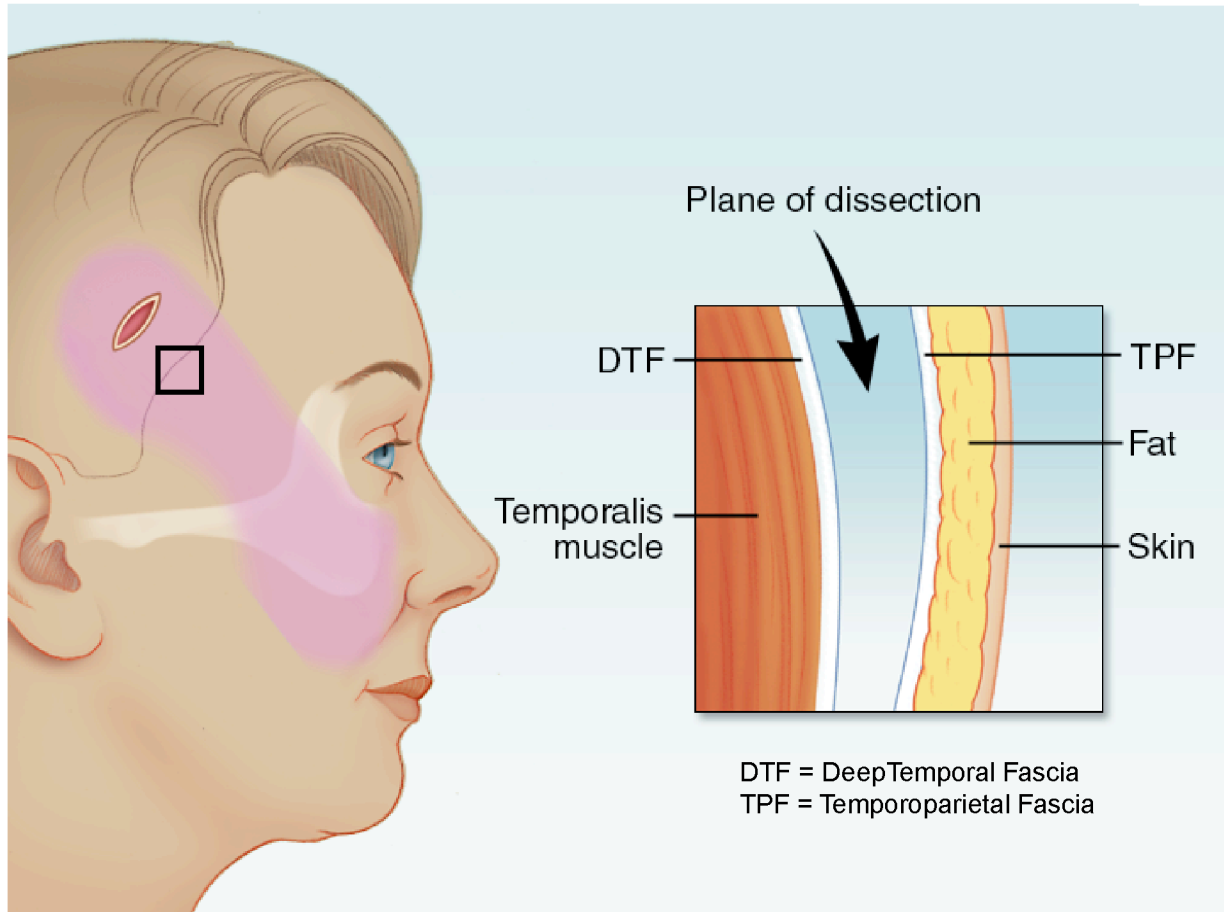
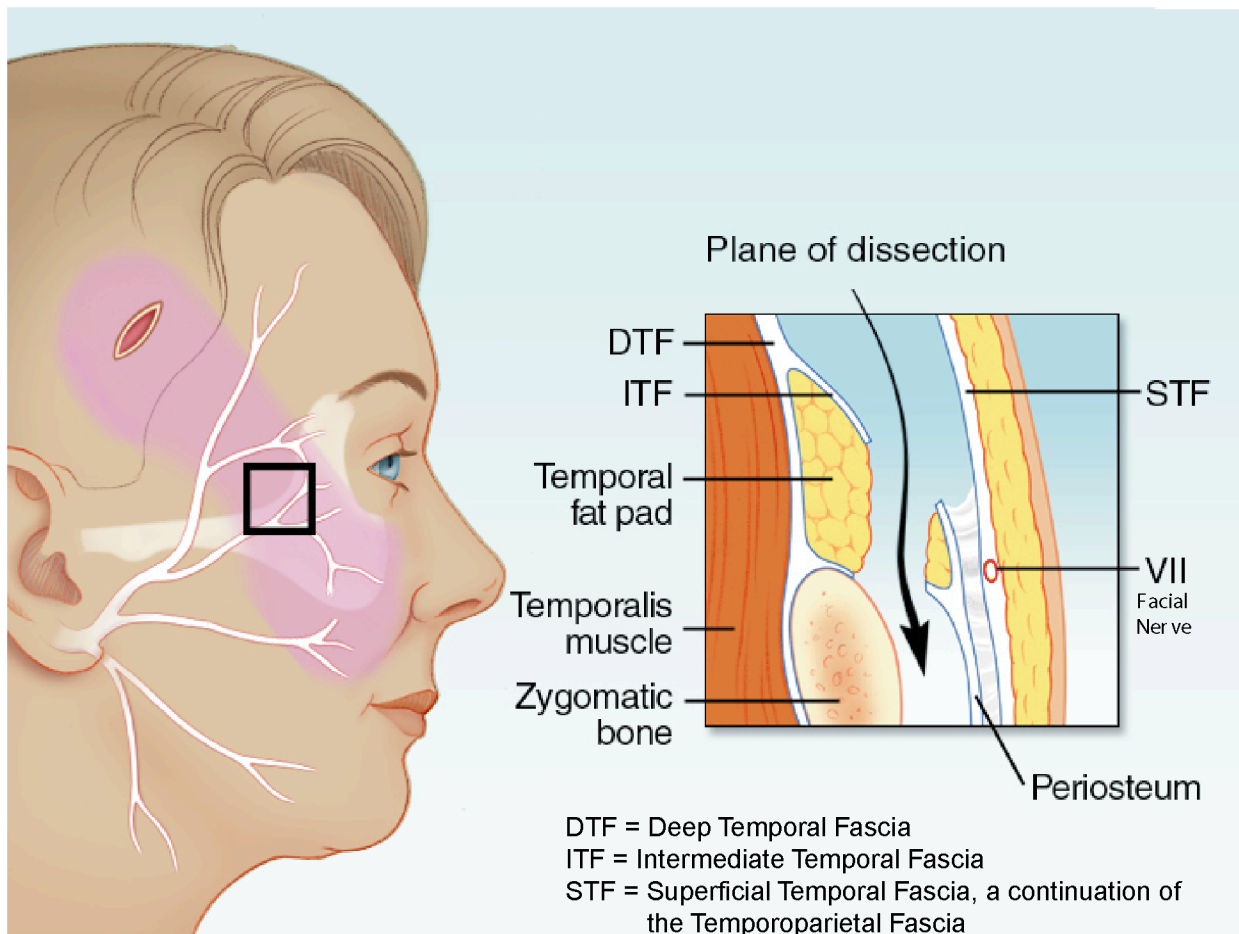


# Endotine Midface™ ST

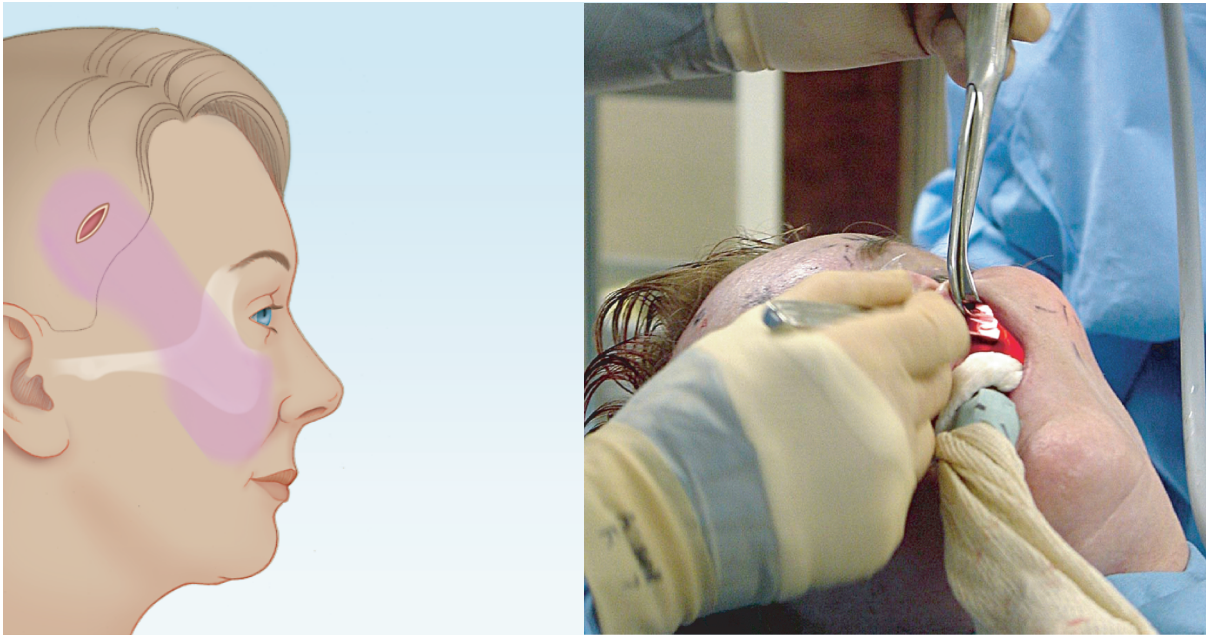
## Temporal Dissection



## Zygoma Dissection

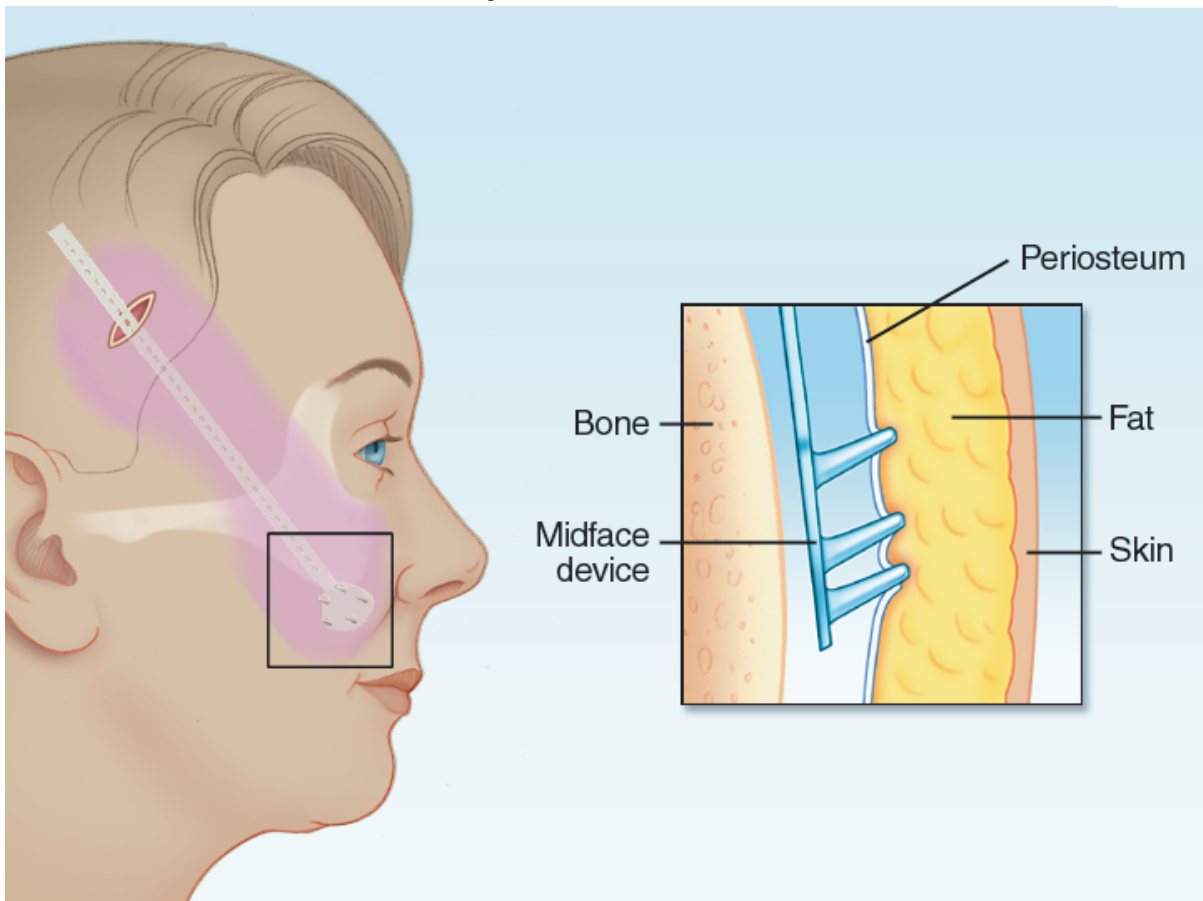


## Lower Midface Dissection



A Buccal Incision is placed above the canine fossa. Use of a lighted Aufricht retractor and headlight will assist in visualization. The dissection plane follows the subperiosteal plane of the maxilla up to the zygoma. Care should be taken to avoid the Infraorbital Nerve. Horizontally, the dissection plane extends from the nasolabial fold to the inferior margin of the maxilla.

## Implant Placement



The Midface Multipoint Platform should initially be positioned near the nasolabial fold, so that when the cheek is elevated, the tine platform rests inferior to the zygoma in the maxillary antrum.